

Subcutaneous Fissurotomy: A Novel Procedure for Chronic Fissure-in-ano. A Review of 109 Cases

Arie E. Pelta, M.D., Kurt G. Davis, M.D., David N. Armstrong, M.D., F.R.C.S
Georgia Colon & Rectal Surgical Clinic, Atlanta, Georgia

PURPOSE: The constant presence of a narrow subcutaneous tract extending caudad to chronic fissures-in-ano is reported. The efficacy of surgically unroofing this tract (subcutaneous fissurotomy) without sphincterotomy was evaluated. **METHODS:** By using a narrow-gauge, hooked probe, a constant, midline subcutaneous tract was identified extending from the caudad aspect of chronic anal fissures. These tracts are present within the sentinel tag, when present, and extend up to 1 cm caudad to the fissure in the subcutaneous plane. A proximal connection with the dentate line in the submucous plane also was identified. Surgically unroofing the tract (subcutaneous fissurotomy) resulted in significant widening of the distal anal canal, rendering internal sphincterotomy unnecessary. A 32-month prospective evaluation of this new technique was performed. Inclusion criteria included patients with chronic anal fissures that had failed conservative therapy, including topical agents. In each case, the tract was identified and surgically laid open along its entire length. No internal sphincterotomy was performed in any patient. Postoperatively, patients were instructed to apply topical 10 percent metronidazole *t.i.d.* The need for repeat surgery and/or subsequent internal sphincterotomy was recorded. **RESULTS:** A total of 109 patients were enrolled during the study period. Median follow-up was 12 months. During the study period, two patients (1.8 percent) required repeat surgery for persistent symptoms at 3 and 12 months postoperatively. No change in continence was reported in any patient. **CONCLUSIONS:** Laying open the subcutaneous tract has a very high success rate and a low incidence of

repeat surgery. This finding introduces a new debate relating to the etiology of fissure-in-ano and makes routine internal sphincterotomy unnecessary. [Key words: Anal fissure; Fissure; Chronic fissure; Fissurotomy; Fissurectomy; Internal sphincterotomy]

Chronic anal fissures are classically identified by fibrotic induration of the fissure edges, a sentinel tag distally and a hypertrophied anal papilla proximally. Surgery is reserved for refractory fissures that fail dietary modification and a number of topical agents. Left-lateral internal sphincterotomy is currently the standard for refractory anal fissures and is considered superior to a posterior midline sphincterotomy, which may result in a keyhole deformity.¹⁻⁴

The morbidity of fecal incontinence from internal sphincterotomy was thought to be rare, but others have reported the incidence to be as high as 31 percent.⁵⁻⁷ Additionally, persistence of fissures is reported in up to 10 percent of patients after internal sphincterotomy.⁶⁻⁹

The constant presence of a subcutaneous tract extending caudad from chronic fissures and extending into sentinel tags (when present) was identified by the senior author (DNA). These tracts were surgically explored by using a narrow-gauge lacrimal probe and were found to extend caudally for 1 cm or more in the subcutaneous plane. Excising the sentinel tag and laying open these tracts resulted in a significant "release" of the perianal skin and a widening of the diameter of the anal canal. The release of the perianal skin resulted in such significant widening of the anal canal that performing internal sphincterotomy was considered unnecessary or even potentially problematic. This study examines

Dr. Armstrong has a patent licensing agreement with SLA Pharma AG for topical 10 percent metronidazole.

Poster presentation at the meeting of The American Society of Colon and Rectal Surgeons, St. Louis, Missouri, June 2 to 6, 2007.

Correspondence to: David N. Armstrong, M.D., F.R.C.S, Georgia Colon & Rectal Surgical Clinic, 5555 Peachtree Dunwoody Road, Suite 206, Atlanta, Georgia, e-mail: GACRS@aol.com

Dis Colon Rectum 2007; 50: 1662-1667

DOI: 10.1007/s10350-007-9022-5

© The American Society of Colon and Rectal Surgeons

Published online: 22 August 2007

the efficacy of this new technique, which we have called a subcutaneous fissurotomy in the treatment of chronic anal fissures.

PATIENTS AND METHODS

Surgical Technique

By using a narrow-gauge, hooked probe, a constant, midline subcutaneous tract was identified extending from the caudal aspect of chronic anal fissures (Figs. 1 and 2). Conventional hooked fistula probes are generally too large to identify the tracts, and gentle probing by using a narrow-gauge hooked probe is required. Surgically unroofing the tract (subcutaneous fissurotomy) resulted in significant widening of the distal anal canal, rendering internal sphincterotomy unnecessary.

A 32-month prospective evaluation of this new technique was performed. Inclusion criteria included chronic anal fissures that had failed conservative therapy (usually 4–6 weeks), including topical agents. In each case, the tract was identified and surgically laid open along its entire length. The residual sentinel tag and skin edges were excised, and the base of the tract cauterized for hemostasis (Fig. 3). The hypertrophied papilla at the level of the dentate line also was excised, when present (Fig. 4). No internal sphincterotomy was performed in any patient. Patients were instructed to take a fiber supplement daily, increase their fluid intake, and were prescribed oxycodone 5 mg by mouth every four hours as needed. Patients also were instructed to apply topical 10 percent metronidazole *t.i.d.* (SLA Pharma, AG) to the surgical site for three to six weeks until the surgical site was healed.

Enrollment criteria were patients with a chronic fissure-in-ano who had failed dietary modification and had failed to respond to topical pharmaceutical agents. A chronic fissure was identified in all patients, manifest by indurated, fibrotic fissure edges and usually with a sentinel tag at the caudad aspect of the fissure and a hypertrophied anal papilla in the proximal aspect. All procedures were performed by the senior author. The primary end point was successful symptom resolution, not requiring repeat surgical intervention. Patients with chronic anal fissure who had undergone a subcutaneous fissurotomy from January 2004 to August 2006 were entered prospectively into a computer database and analyzed. The need for repeat surgery and/or subsequent internal sphincterotomy was recorded. Patients were followed

up at three and six weeks postoperatively and then as clinically indicated. Healing of the tract was evaluated by visual inspection or anoscopy.

RESULTS

A total of 109 patients were studied during a 32-month period. Median follow-up was 12 months. The subcutaneous tracts were identified in all cases, and no internal sphincterotomy was performed in any patient. Patients reported early pain relief after the procedure, even in the presence of an “open” skin defect resulting from laying open the tract. The tract healed by secondary intention during the four to six weeks after surgery, when it was typically healed (Fig. 5). During the study period, 107 patients (98.2 percent) experienced symptomatic resolution and 2 patients (1.8 percent) required repeat surgery for persistent symptoms.

One patient (42-year-old male) initially failed conservative treatment with fiber supplements and later use of topical nifedipine and underwent subcutaneous fissurectomy for a posterior fissure. Three months later, the patient underwent repeat surgery for persistent symptoms and was found to have an additional anterior fissure, which was treated by subcutaneous fissurotomy and left-lateral internal sphincterotomy.

The second patient (45-year-old female) had a recurrence of posterior fissure symptoms one year after a subcutaneous fissurotomy, and she underwent examination under anesthesia. No subcutaneous tract

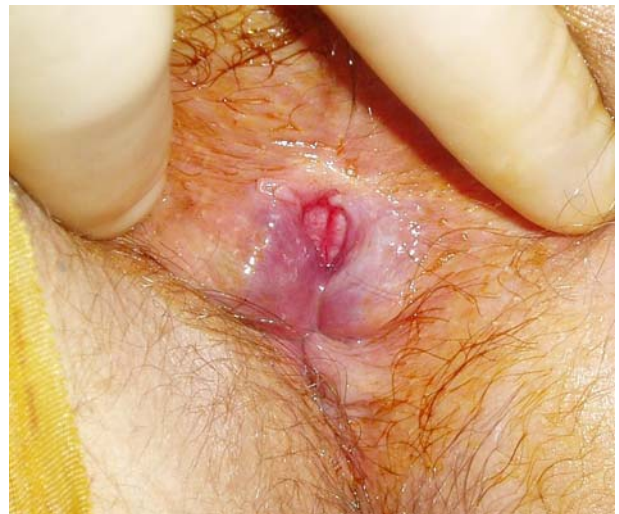

Figure 1. A classic, chronic anal fissure, with indurated edges, and internal sphincter fibers visible in its base.

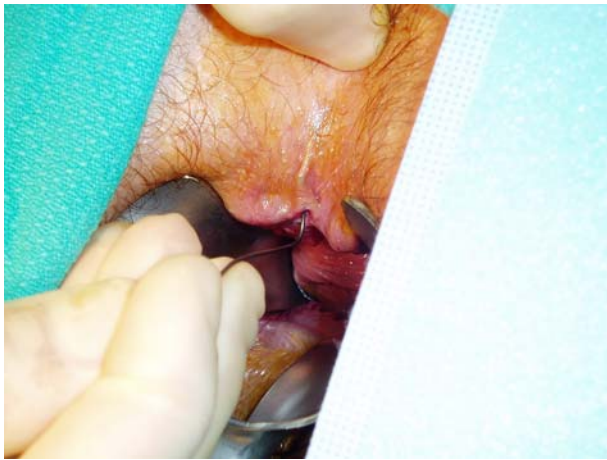

Figure 2. The subcutaneous tract extends approximately 1 cm from the caudad aspect of the fissure and is identified using a narrow-gauge hooked probe, before laying open.

was identified, and therefore, a left-lateral internal sphincterotomy was performed.

During this same time period, a third patient, who had undergone cautery of a fissure and internal sphincterotomy three years previously, underwent repeat surgery for persistent fissure symptoms. A recurrent posterior midline fissure was identified and he underwent a subcutaneous fissurotomy, again without sphincterotomy. No change in continence was reported in any patient.

DISCUSSION

Internal sphincterotomy is not without hazard. A major complication of internal sphincterotomy is fecal incontinence in anywhere from 5 to 31 percent of patients.⁷⁻¹² The fecal incontinence does not always recover, even after long-term follow-up. In one study of 68 patients undergoing internal sphincterotomy, fissures healed in 97 percent of patients, whereas 10.3 percent were incontinent and did not improve with time.⁸ Nonetheless, lateral internal sphincterotomy is currently the standard of care for surgical treatment of fissures and is regarded as a safe and effective treatment, which only occasionally impairs continence.¹

Before the widespread acceptance of left-lateral internal sphincterotomy, several “historic” procedures focused on obliterating all three components of the fissure: the fissure itself, the sentinel tag, and the hypertrophied papilla.¹³ Excision of a 4-cm triangle of skin in relation to the fissure was described by Gabriel, and subsequent skin grafting

of the defect was added by Hughes. Posterior sphincterotomy, as described by Eisenhammer, included removing the sentinel tag and the hypertrophied papilla, as well as dividing the posterior internal sphincter. Each of these procedures would have opened up the subcutaneous tract described herein; however, they fell into disuse because of their overly aggressive nature, prolonged hospitalization, and wound healing times, and the formation of keyhole defects after posterior sphincterotomy.^{4,13}

The internal sphincter is probably the “innocent bystander” in fissure disease. The higher sphincter tones, well known to all who operate on fissures, are a result of direct sphincter irritation from a deep fissure eroding into the sphincter fibers. Chemical relaxation of the sphincter or surgical releasing the sphincter by sphincterotomy reduces sphincter tone and therefore results in symptomatic relief.¹⁴ A number of topical agents have demonstrable effect in fissure pain relief. Topical nitroglycerin ointment 0.2 percent has reported healing rates as high as 67 percent, whereas topical diltiazem 2 percent and nifedipine 0.3 percent have healing rates of 95 percent.¹⁵⁻¹⁹ However, these agents may be accompanied by unwanted side effects, such as headache and hypotension. Botulinum toxin injection of the internal sphincter produces a transient chemical sphincterotomy with a 20 percent failure rate requiring repeated treatments.²⁰

We propose that the primary causative event in fissure formation is shearing trauma, which results in a

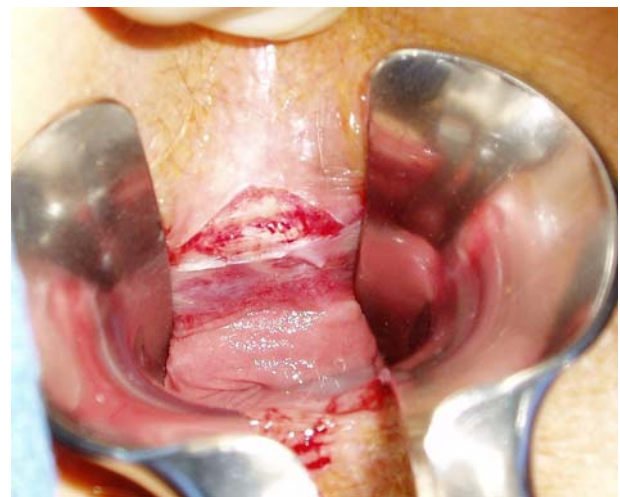


Figure 3. Laying open the entire length of the tract results in a significant widening of the anal verge. This renders internal sphincterotomy unnecessary, and even potentially problematic.

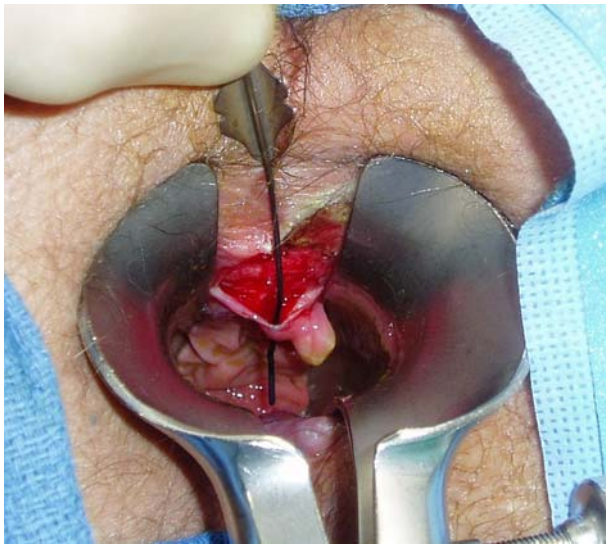


Figure 4. The connection with the dentate line is opened in the submucosal plane. Note the hypertrophied papilla at the level of the dentate line.

subcutaneous sinus, which fails to heal because of undrained “smouldering” infection. This causes irritation of the internal sphincter, increased sphincter tone, and characteristic anorectal pain. Sphincterotomy, diltiazem, nitroglycerin, and botulinum toxin each causes relaxation of the internal sphincter, with resulting symptomatic relief. We believe this sequence of events is more logical and clinically recognizable than the alternative argument, which suggests that primary internal sphincter hypertonicity is the causative event and the fissure develops as a secondary phenomenon.

Doppler blood flow studies suggest that ischemia of the posterior midline anal canal may be a causative factor in fissure disease.^{21,22} However, the presence of the subcutaneous tract reported in the current study may explain the lower blood flows reported, as artifactual readings from the presence of the tract itself.

Previous prospective, randomized studies report the successful practice of excising the hypertrophied papilla during fissure surgery, and this practice improves patient outcomes from a 58 percent satisfaction rate after internal sphincterotomy alone to 84 percent after adding papilla excision.²³ However, no mention is made of excising the sentinel tag in this study, and no firm conclusion can be drawn.

In our study, we demonstrated a 98.2 percent healing rate after the new procedure. After internal sphincterotomy, persistence of anal fissures has been reported to be as high as 10 percent, which far exceeds

the 1.8 percent recurrence rate in our series.^{6-9,24} Despite these findings, internal sphincterotomy still has a role in treating those patients who experience recurrent symptoms after subcutaneous fissurotomy.

One additional variable in the current study was the use of topical metronidazole, which also may promote healing of the fissurotomy incision. Previous studies have demonstrated the benefits of oral and intravenous metronidazole after hemorrhoidectomy.²⁵ The use of topical metronidazole avoids unwanted side effects of the systemic medication, such as paresthesia, nausea, and a metallic taste in the mouth. Although topical 10 percent metronidazole has demonstrated efficacy after hemorrhoidectomy and in anorectal Crohn’s disease, the impact of the medication after this procedure is not known and requires further study.^{26,27}

The potential benefits of avoiding internal sphincterotomy are obvious. A high rate of success was accomplished by performing a modified fissurotomy and avoiding internal sphincterotomy. This questions the need for routine internal sphincterotomy for fissure-in-ano and further questions the etiology of anal fissures in the first place.

We postulate that the cause of an anal fissure may be local shearing trauma to the posterior midline skin, causing the original fissure defect and resulting in a traumatic sinus tract manifest by the sentinel tag. In the case of diarrhea, local skin breakdown may be the initiating event. With subsequent bowel movements, stool may be forced against the caudal margin of the fissure and into the subcutaneous

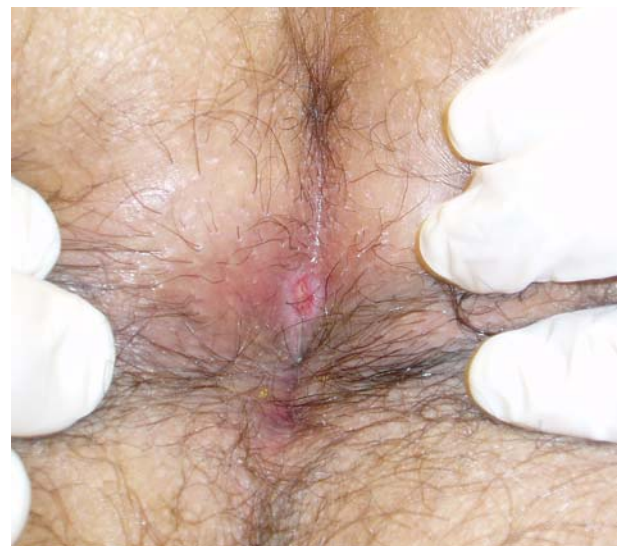

Figure 5. Four weeks after surgery, the tract has healed by secondary intention, including the original fissure.

sinus tract, which fails to heal because of chronic infection and inadequate drainage. Surgical “release” of this sinus tract and drainage of the tract results in pain relief and subsequent healing of the site by secondary intention

CONCLUSIONS

The presence of a subcutaneous tract in relation to the caudad aspect of chronic fissures is a novel finding. Chronic fissures (and specifically the associated sentinel tags) may persist because of “smoldering” sepsis within the sinus tract. Laying open the tract allows drainage of the area and surgically releases the distal anal canal. The demonstration of reduced blood flow in that specific location may be explained on the basis of artifactual lower readings as a result of the subcutaneous tract.^{21,22} The results of the current study are consistent with the role of the internal sphincter as the “innocent bystander” rather than a primary cause of fissure. By avoiding routine internal sphincterotomy, the risk of anorectal incontinence is practically eliminated. The efficacy of subcutaneous fissurotomy for chronic fissure-in-ano requires further randomized study.

REFERENCES

- Orsay C, Rakinic J, Perry WB, *et al.* Standards Practice Task Force, The American Society of Colon and Rectal Surgeons. Practice parameters for the management of anal fissures (revised). *Dis Colon Rectum* 2004;47:2003–7.
- Nelson RL. Meta-analysis of operative techniques for fissure-in-ano. *Dis Colon Rectum* 1999;42:1424–31.
- Romono G, Rotondano G, Santangelo M, *et al.* A critical appraisal of the pathogenesis and morbidity of surgical treatment of chronic anal fissure. *J Am Coll Surg* 1994;178:600–4.
- Abcarian H. Surgical correction of chronic anal fissure: results of lateral internal sphincterotomy *vs.* fissurectomy—midline sphincterotomy. *Dis Colon Rectum* 1980;23:31–6.
- Garcia-Aguilar J, Belmonte C, Wong WD, *et al.* Open *vs* closed sphincterotomy for chronic anal fissure: long-term results. *Dis Colon Rectum* 1996;39:440–3.
- Khubchandani IT, Reed JF. Sequelae of internal sphincterotomy for chronic fissure-in-ano. *Br J Surg* 1989;76:431–4.
- Casillas S, Hull TL, Zutshi M, *et al.* Incontinence after a lateral internal sphincterotomy: are we underestimating it. *Dis Colon Rectum* 2005;48:1193–9.
- Rotholtz NA, Bun M, Mauri MV, *et al.* Long-term assessment of fecal incontinence after lateral internal sphincterotomy. *Tech Coloproctol* 2005;9:115–8.
- Wiley M, Day P, Rieger N, *et al.* Open *vs.* closed lateral sphincterotomy for idiopathic fissure-in-ano: a prospective, randomized, controlled trial. *Dis Colon Rectum* 2004;47:847–52.
- Hyman N. Incontinence after lateral internal sphincterotomy: a prospective study and quality of life assessment. *Dis Colon Rectum* 2004;47:35–8.
- Pernikoff BJ, Eisenstat TE, Rubin RJ, *et al.* Reappraisal of partial lateral internal sphincterotomy. *Dis Colon Rectum* 1994;37:1291–5.
- Nyam DC, Pemberton JH. Long-term results of lateral internal sphincterotomy for chronic anal fissure with particular reference to incidence of fecal incontinence. *Dis Colon Rectum* 1999;42:1306–10.
- Goligher J. Surgery of the anus, rectum and colon. Anal fissure. 5th ed. London, 1984:150–66.
- Ram E, Alper D, Gideon Y, *et al.* Internal anal sphincter function following lateral internal sphincterotomy for anal fissure. A long-term manometric study. *Ann Surg* 2005;242:208–11.
- Thornton MJ, Kennedy ML, King DW. Manometric effect of topical glyceryl trinitrate and its impact on chronic anal fissure healing. *Dis Colon Rectum* 2005;48:1207–12.
- Antropoli C, Perrotti P, Rubino M, *et al.* Nifedipine for local use in conservative treatment of anal fissures: preliminary results of a multicenter study. *Dis Colon Rectum* 1999;42:1011–5.
- Kocher HM, Steward M, Leather AJ, Cullen PT. Randomized clinical trial assessing the side-effects of glycerol trinitrate and diltiazem hydrochloride in the treatment of chronic anal fissure. *Br J Surg* 2002;89:413–7.
- Perrotti P, Bove A, Antropoli C, *et al.* Topical nifedipine with lidocaine ointment *vs.* active control for treatment of chronic anal fissure: results of a prospective, randomized, double-blind study. *Dis Colon Rectum* 2002;45:1468–75.
- Jonas M, Neal KR, Abercrombie JF, Scholefield JH. A randomized trial of oral *vs.* topical diltiazem for chronic anal fissures. *Dis Colon Rectum* 2001;44:1074–8.
- Minguez M, Herreros B, Espi A, *et al.* Long-term followup (42 months) of chronic anal fissure after healing with botulinum toxin. *Gastroenterology* 2002;123:112–7.
- Schouten WR, Briel JW, Auwerda JJ. Relationship between anal pressure and anodermal blood flow. The vascular pathogenesis of anal fissures. *Dis Colon Rectum* 1994;37:664–9.
- Schouten WR, Briel JW, Auwerda JJ, *et al.* Ischaemic nature of anal fissure. *Br J Surg* 1996;81:63–5.

23. Gupta PJ, Kalaskar S. Removal of hypertrophied anal papillae and fibrous anal polyps increases patient satisfaction after anal fissure surgery. *Tech Coloproctol* 2003;7:155–8.
24. Ravikumar TS, Sridahr S, Rao RN. Subcutaneous lateral internal sphincterotomy for chronic fissure-in-ano. *Dis Colon Rectum* 1982;25:798–801.
25. Carapeti EA, Kamm MA, McDonald PJ, Phillips RK. Double-blind randomized controlled trail the effect of metronidazole on pain after day case hemorrhoidectomy. *Lancet* 1998;351:169–72.
26. Nicholson TJ, Armstrong DN. Topical metronidazole (10 percent) decreases posthemorrhoidectomy pain and improves healing. *Dis Colon Rectum* 2004;47:711–6.
27. Stringer E, Nicholson TJ, Armstrong DN. Efficacy of topical metronidazole (10 percent) in the treatment of anorectal Crohn's disease. *Dis Colon Rectum* 2005;48:970–4.