

# Harmonic Scalpel® vs. Electrocautery Hemorrhoidectomy: A Prospective Evaluation

David N. Armstrong, M.D., F.R.C.S., Wayne L. Ambroze, M.D.,  
Marion E. Schertzer, M.D., Guy R. Orangio, M.D.

*From the Georgia Colon and Rectal Surgical Clinic, Atlanta, Georgia*

**INTRODUCTION:** Management of posthemorrhoidectomy pain remains a very unsatisfactory clinical dilemma. Compared with electrocautery and laser, the Harmonic Scalpel® causes minimal lateral thermal injury during tissue dissection. **PURPOSE:** The aim of the study was to establish whether decreased lateral thermal injury translated into diminished posthemorrhoidectomy pain. **METHODS:** A prospective randomized trial comparing Harmonic Scalpel® hemorrhoidectomy and electrocautery was undertaken. Fifty consecutive patients were randomized into two groups: Harmonic Scalpel® and electrocautery hemorrhoidectomy. The indications included Grade III internal hemorrhoids with external components or Grade IV disease. Patients with additional anorectal pathology (fissure or fistula) were excluded, as were patients with neurologic deficits, chronic pain syndrome, and those already taking narcotic analgesics. Pain was assessed using a visual analog scale preoperatively and on postoperative Days 1, 2, 7, 14, and 28. Twenty-four-hour narcotic usage (Hydrocodone, 10 mg) was recorded on postoperative Days 1, 2, 7, 14, and 28. A three-quadrant modified Ferguson hemorrhoidectomy was performed with each patient in the prone jackknife position. **RESULTS:** Pain in the Harmonic Scalpel® hemorrhoidectomy group was significantly less than in electrocautery patients on each postoperative day studied. Analgesic requirements were also significantly less in the Harmonic Scalpel® group on Days 1, 2, 7, and 14. There was no correlation between postoperative pain and grade of hemorrhoid, status of the surgical incision (open vs. closed), or any other study variable. Fifty-five percent of Harmonic Scalpel® patients returned to work within one week of surgery, compared with 23 percent of electrocautery patients. **CONCLUSION:** The study demonstrates significantly reduced postoperative pain after Harmonic Scalpel® hemorrhoidectomy compared with electrocautery controls. The diminished postoperative pain in the Harmonic Scalpel® group likely results from the avoidance of lateral thermal injury. [Key words: Hemorrhoidectomy; Postoperative pain; Postoperative analgesia; Harmonic Scalpel®]

Armstrong DN, Ambroze WL, Schertzer ME, Orangio GR. Harmonic Scalpel® vs. electrocautery hemorrhoidectomy: a prospective evaluation. *Dis Colon Rectum* 2001;44:558-564.

**S**urgical hemorrhoidectomy is a notoriously painful procedure. Much research over the last two decades has concentrated on reducing posthemor-

rhoidectomy pain resulting from these surgical incisions. Research has been concentrated in three areas: analgesic delivery during the postoperative period; modification of the technique of surgical hemorrhoidectomy; and the use of a variety of surgical instruments (most notably laser) in the hopes of decreasing postoperative pain.<sup>1-5</sup>

Alternatives to traditional oral narcotic analgesics for postoperative pain have included subcutaneous morphine infusion,<sup>1</sup> transdermal fentanyl,<sup>2</sup> and parenteral Toradol® (Roche, Nutley, NJ) administration.<sup>3</sup> Modifications of the surgical technique have included open, semiopen,<sup>6</sup> and closed incisions,<sup>7</sup> routine performance of lateral internal sphincterotomy,<sup>8</sup> and the use of stapling devices<sup>9</sup> (both linear and circular). No technique has been conclusively demonstrated to be superior.<sup>10-13</sup> Laser hemorrhoidectomy gained widespread publicity but has never been conclusively demonstrated to be superior to conventional hemorrhoidectomy.<sup>14-19</sup> Nd:YAG lasers are more effective coagulators but produce significant thermal injury. CO<sub>2</sub> lasers are effective cutting instruments and produce less thermal injury, but they provide poor hemostasis. Consequently, a combination of both lasers is sometimes necessary to complete the procedure, a cumbersome and expensive undertaking.<sup>14, 15</sup>

The rationale for evaluating the use of the Harmonic Scalpel® (Johnson & Johnson Medical K.K., Ethicon Endo-Surgery, Cincinnati, OH) for surgical hemorrhoidectomy lay in the relatively low temperatures at which the Harmonic Scalpel® divides tissue, compared with laser and electrocautery.<sup>20, 21</sup> This results in a decreased lateral thermal injury. The Harmonic Scalpel® divides tissue using high-frequency ultrasonic energy, which disrupts protein hydrogen bonds within the tissue. Blood vessels are coapted and sealed by denatured proteins in the vessel lumen. The relatively low temperature (80°C) at which this takes place results in minimal thermal injury (<1.5 mm). In contrast, both electrocautery and laser divide

Address reprint requests to Dr. Armstrong: Georgia Colon and Rectal Surgical Clinic, 5555 Peachtree Dunwoody Road NE, Atlanta, Georgia 30342.

tissue by a process of thermal coagulation, which results in a significant lateral thermal injury, or burn, several millimeters deep. It was considered that avoiding or minimizing the lateral thermal injury may translate into decreased posthemorrhoidectomy pain after Harmonic Scalpel® hemorrhoidectomy. This rationale prompted a prospective evaluation of postoperative pain and narcotic analgesic requirements after Harmonic Scalpel® hemorrhoidectomy *vs.* electrocautery controls.

## MATERIALS AND METHODS

Fifty patients requiring surgical hemorrhoidectomy were prospectively randomized into one of two groups: the Harmonic Scalpel® and electrocautery groups. The indications for the hemorrhoidectomy in each patient were either Grade III, symptomatic internal hemorrhoids in association with large external components or prolapsed, thrombosed, Grade IV hemorrhoids. The presence of additional anorectal pathology such as fissure- or fistula-in-ano was excluded from the current study. Patients with neurologic deficit (paraplegia or previous cerebrovascular accident) or chronic pain syndrome and patients already taking narcotic analgesics were also excluded. Informed consent was obtained from all patients. Four surgeons (the listed authors) participated in the study.

The technique of surgical hemorrhoidectomy was standardized in each case. The patient was placed in the prone jackknife position under general anesthesia, local anesthesia plus intravenous sedation (local monitored anesthesia care), or spinal anesthesia. A modified Ferguson three-quadrant hemorrhoidectomy was performed in each patient, using either the Harmonic Scalpel® or electrocautery. The technique of Harmonic Scalpel® hemorrhoidectomy is the same as electrocautery, except that the Harmonic Scalpel® uses the "scissor" configuration (Coagulating Shears® model). Patients requiring a one-, two-, or four-quadrant hemorrhoidectomy were excluded from the study. The surgical incisions were closed in the majority of patients; however, depending on the surgical anatomy, some were left open where appropriate. Management of the incision was individualized in each patient, and the status of the surgical defect (open *vs.* closed) was recorded. The variables in Table 1 were recorded for each patient.

Postoperative pain was evaluated by means of a visual analog scale, which was explained to the pa-

**Table 1.**  
Patient Demographics and Study Variables

Variable	Harmonic Scalpel® (n = 25)	Electrocautery (n = 25)	P Value
Age (yr)	49.2 ± 2.6*	43.6 ± 1.6*	NS
Gender			NS
Male	13	12	
Female	12	13	
Previous surgery			NS
Yes	2	3	
No	23	22	
Grade			NS
III	20	24	
IV	5	1	
Incision			NS
Open	8	4	
Closed	17	21	
Preoperative pain	4.0 ± 0.6*	2.9 ± 0.7*	NS

NS = not significant.

Two-sample *t*-test was used to test ages between groups; chi-squared test was used for gender; Fisher's exact test was used for grade, previous surgery, and incision; Wilcoxon's rank-sum test was used for preoperative pain.

\* Values are mean ± standard error of the mean.

tient during the preoperative history and physical examination. The pain was evaluated by a score of 0 (no pain) to 10 (very severe pain). The patient was asked to evaluate the pain both preoperatively and on postoperative Days 1, 2, 7, 14, and 28. Postoperative analgesic requirements were evaluated by prescribing a standard narcotic analgesic (hydrocodone, 10 mg by mouth every four to six hours as needed). The patients were asked to keep a careful record of the number of narcotic analgesics required during each 24-hour period on postoperative Days 1, 2, 7, 14, and 28. This was recorded on the patient information sheet. Patients were seen at two weeks and four weeks postoperatively, and the completed data sheets were collected at the four-week visit.

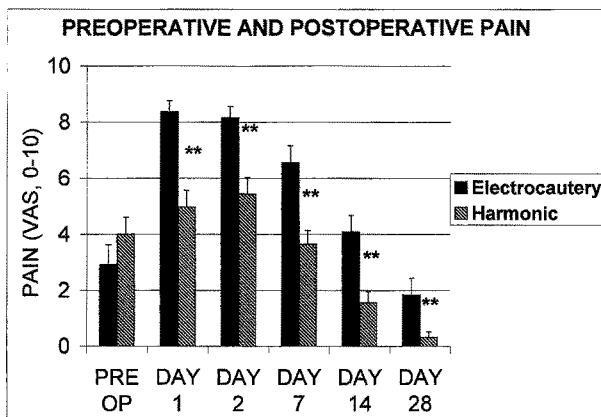
Mean pain scores for each study day in each group were compared using Wilcoxon's rank-sum test. In addition, preoperative pain scores were subtracted from postoperative pain scores in each patient to derive a "net" pain score for each postoperative day. These were then compared using Wilcoxon's rank-sum test. The numbers of narcotic analgesics required in each group were compared using a two-sample *t*-test.

RESULTS

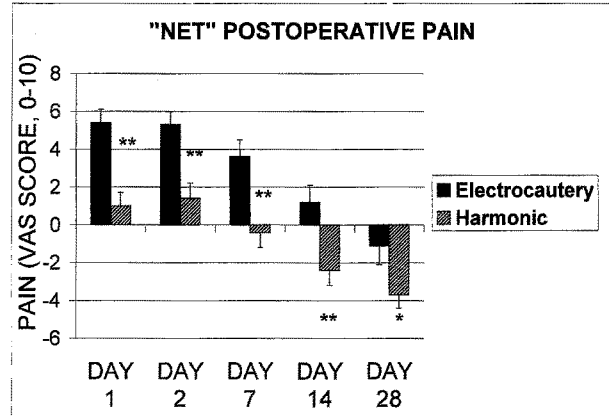
Twenty-one patients were excluded from the study because of coexisting anorectal disease (fissure or fistula) or neurologic or cognitive impairment (hemiplegia or stroke). The remaining study patients in each group were enrolled chronologically (from date of surgery). The first 25 patients from each group were used to compare the two procedures. This number was based on the results of a previous pilot study (with ten patients in each group), which revealed statistical significance at most, but not all, postoperative days studied. No patient was lost to follow-up.

Patient demographics are summarized in Table 1. The two groups were comparable in terms of age and gender distribution. Similarly, there was no significant difference between the groups in admission status, type of anesthesia, grade of hemorrhoid, previous anorectal surgery, or incision status. Preoperative pain experienced by the patients was similar between the two groups. Postoperative pain was significantly less in the Harmonic Scalpel® group on Days 1, 2, 7, 14, and 28 (Fig. 1). "Net" postoperative pain scores were also significantly lower in the Harmonic Scalpel® group on each of the postoperative days (Fig. 2).

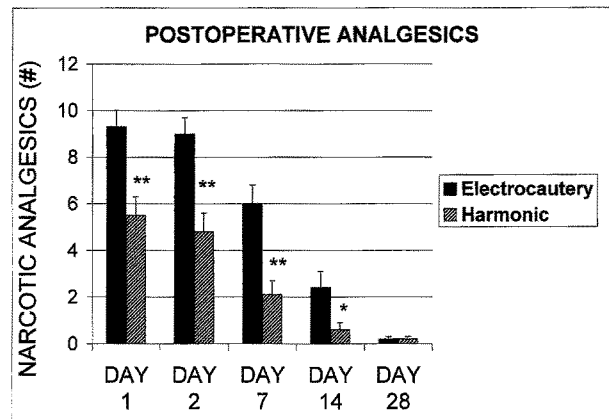
The number of narcotic analgesics required per 24-hour period was significantly lower in the Harmonic Scalpel® group on Days 1, 2, 7, and 14. By Day 28, there was no significant difference between the groups (Fig. 3). There was no significant correlation between postoperative pain and hemorrhoidal grade



**Figure 1.** Pain scores (visual analog scores (VAS)) before (pre op) and after Harmonic Scalpel® and electrocautery hemorrhoidectomy. Preoperative pain was similar between the two groups. Harmonic Scalpel® patients experienced significantly less pain than electrocautery controls on all postoperative days (\*\**P* < 0.01, Wilcoxon's rank-sum test).



**Figure 2.** Net pain scores (postoperative scores minus preoperative scores) after Harmonic Scalpel® and electrocautery hemorrhoidectomy. Harmonic Scalpel® patients experienced significantly less postoperative pain than electrocautery controls (\*\**P* < 0.01, \**P* < 0.05, Wilcoxon's rank-sum test). VAS = visual analog.



**Figure 3.** Analgesic requirements after Harmonic Scalpel® and electrocautery hemorrhoidectomy. Harmonic Scalpel® patients required significantly fewer narcotic analgesics on postoperative Days 1, 2, 7, and 14. By Day 28, no significant difference existed between the groups (\*\**P* < 0.01, \**P* < 0.05, Wilcoxon's rank-sum test).

(Grade III or IV), incision status (open vs. closed), or any other study variable.

Approximately half of the patients reported full-time employment (18 in the Harmonic Scalpel® group and 13 in the electrocautery group). There was great variability in time taken off work, ranging from one day to two months in the Harmonic Scalpel® group and three days to three months in the electrocautery group. Because of the small number of patients involved, statistical analysis was not performed. To examine time off work in a qualitative manner, the percentage of patients in each group requiring one, two, three, or more than three weeks off work was

calculated and is summarized in Table 2. Fifty-five percent of patients in the Harmonic Scalpel® group returned to work within one week, compared with 23 percent in the electrocautery group. Sixteen percent of Harmonic Scalpel® patients required more than three weeks off work, compared with 23 percent in the electrocautery group.

One patient in the Harmonic Scalpel® group developed urinary retention requiring a Foley® catheter (Bard Urological Co., Covington, GA) for 36 hours. No patient in either group experienced a postoperative hemorrhage requiring surgical intervention.

## DISCUSSION

Surgical hemorrhoidectomy is generally reserved for symptomatic, Grade III internal hemorrhoids with external components or for Grade IV hemorrhoids. For internal hemorrhoids alone (Grade I, II, or III), less invasive means of hemorrhoidal fixation are appropriate.<sup>22</sup> These may include rubber band ligation, cryoablation, or infrared coagulation. Fixation procedures can be performed in the office, require little if any time off work, and are much less painful than surgical hemorrhoidectomy. If fixation procedures are attempted in the presence of external components, the resulting venous congestion produces painful engorgement of the external hemorrhoid, which frequently requires urgent surgical hemorrhoidectomy. The combination of external hemorrhoids and Grade III or IV hemorrhoids is therefore most effectively treated by excision of the hemorrhoidal complex.<sup>23</sup> The obvious disadvantage of surgical hemorrhoidectomy is the postoperative pain resulting from the surgical defect in the sensitive perianal skin and anoderm. Much of this discomfort may arise from the thermal injury from the use of electrocautery or laser.

The list of new surgical technologies claiming to decrease posthemorrhoidectomy pain is long. Most of the reported benefits escape formal prospective randomized evaluation. The hype surrounding other technologies, lasers being a case in point, continues long after any benefits have been discounted or dis-

proved.<sup>19</sup> This long and unhappy history of new methodologies in hemorrhoidectomy would make most cautious authors think twice before making renewed pronouncements on yet another new technology. The current authors are no exception to this.

The Harmonic Scalpel® possesses the unique advantage of causing very little lateral thermal injury. The device divides tissue by means of high-frequency (55,000 Hz) ultrasonic energy transmitted between the instrument blades. The active blade of the instrument vibrates longitudinally against an inactive blade over an excursion of 50 to 100 microns.<sup>20</sup> One edge of the active blade is relatively sharp, for cutting, and the other is blunt, for coagulation purposes. The scalpel is activated by a foot control, containing a pedal for "full" power mode, used for cutting, and a second pedal for "variable" power mode, for coagulation. The blades are opened and closed using a scissor grip: increased force applied to the grip increases the speed of cutting. A total of four combinations of blade setting and power mode are therefore available, which, together with variable force applied to the grip, provide a range of cutting and coagulation properties. Using the sharp blade, on "full" power mode, and applying a firmer grip to the scissor handle maximize cutting. Coagulation is maximized using the blunt blade, "variable" power mode, and a light grip. The performance of the scalpel in each of these circumstances requires some practice and experience.

The rationale for using the Harmonic Scalpel® in performing surgical hemorrhoidectomy was the concept that a decreased lateral thermal injury (0–1.5 mm deep) at the surgical site may translate into decreased postoperative pain. Studies examining the depth of thermal injury using porcine small bowel mesentery reported a lateral thermal injury up to 240  $\mu\text{m}$  to 15 mm deep using monopolar electrocautery, whereas bipolar electrocautery caused tissue injury from 120  $\mu\text{m}$  to 9 mm deep. CO<sub>2</sub> laser creates an injury 60  $\mu\text{m}$  to 4 mm deep, and Nd:YAG creates an injury 300  $\mu\text{m}$  to 4.2 mm deep.<sup>20</sup>

During the early stages of the evaluation, it soon

**Table 2.**  
Time Off Work in Harmonic Scalpel® and Electrocautery Groups

Time Off Work	<1 week	1–2 weeks	2–3 weeks	>3 weeks	Total
Harmonic Scalpel®	10 (55%)	5 (28%)	0	3 (17%)	18 (100%)
Electrocautery	3 (23%)	4 (31%)	3 (23%)	3 (23%)	13 (100%)

Fifty-five percent of Harmonic Scalpel® patients were able to return to work within a week, compared with 23 percent in the electrocautery group.

became apparent that patients undergoing Harmonic Scalpel® hemorrhoidectomy experienced much less pain than their electrocautery counterparts. One patient in particular, a middle-aged male, underwent Harmonic Scalpel® hemorrhoidectomy for symptomatic Grade III hemorrhoids. The patient had undergone a previous (incomplete) conventional hemorrhoidectomy some ten years earlier. This individual, who was in a unique position to evaluate both forms of hemorrhoidectomy, insisted that the pain experienced after the Harmonic Scalpel® procedure was dramatically less than his prior experience. A pilot study was conducted to compare the Harmonic Scalpel® hemorrhoidectomy with electrocautery, and the clinical impression was confirmed by the results of the pilot study. This prompted a more formal prospective evaluation, which is reported here. The significant reductions in both the postoperative pain experienced by the Harmonic Scalpel® patients and the analgesic requirements reflect an overall decrease in posthemorrhoidectomy pain in the Harmonic Scalpel® group. These results confirm the initial concept that the elimination of a lateral thermal injury does indeed translate into significantly less postoperative pain. An obvious comparison could be made between hemorrhoidectomy using "cold steel" scalpel or scissor hemorrhoidectomy and electrocautery. If bleeding sites are individually ligated, a time-consuming and infrequent surgical practice, no thermal injury whatsoever is imparted. Under these circumstances, posthemorrhoidectomy pain would be expected to compare to that in the Harmonic Scalpel® group or even improve on it. More often, however, supplemental electrocautery is used to a greater or lesser extent during scissor hemorrhoidectomy to coagulate individual bleeders. In contrast, a hypothetical argument may be raised concerning the "painless" nature of deep (third-degree) burns resulting from the destruction of dermal pain fibers. The deep burn of electrocautery is sometimes invoked as a potentially beneficial feature, resulting in less pain than an equivalent "nonthermal" scalpel or scissor incision. However, this argument defies the everyday clinical experience of observing the discomfort, surrounding inflammation, and healing time of a "clean" surgical incision compared with that of a deep thermal burn.

CO<sub>2</sub> lasers also cause a less extensive lateral thermal injury than Nd:YAG, but they have poor hemostatic properties. Laser enthusiasts will point to the CO<sub>2</sub> lasers as an equivalent modality to the Harmonic Scalpel®, albeit with less hemostatic properties. Laser

proponents may interpret the results of the current study not as a unique benefit of the Harmonic Scalpel®, but as a demonstration of the obsolescence of electrocautery. The only means for evaluating this is prospective randomized evaluation among the Harmonic Scalpel®, laser, and possibly a third cold steel arm.

The current study includes only Grade III internal hemorrhoids in association with external components or Grade IV hemorrhoidal disease. Accordingly, variability introduced by operating on lesser grade hemorrhoids (which would normally be treated by fixation techniques) is avoided. This avoidable source of variability is a frequent criticism leveled at previous similar studies. The exclusion of coexisting anorectal pathology (fissure or fistula) makes the current study groups a homogenous population of advanced hemorrhoidal disease. Exclusion of patients with neurologic deficit or chronic pain syndrome and of patients currently taking narcotic analgesics avoided variability in assessing pain.

In the current study, no statistical association was found among the status of the surgical incision, open *vs.* closed, and postoperative pain. This contrasts with the findings of Neto *et al.*,<sup>6</sup> who found a greater requirement for oral narcotics in the early and late postoperative period after "open" hemorrhoidectomy than after "semiopen" procedures. In a similar study, Ho *et al.*<sup>7</sup> reported no difference in postoperative pain scores between "open" and "closed" procedures. Neto *et al.*<sup>6</sup> reported a longer healing time (25.2 days) in "open" patients, compared with 12.2 days in "semiopen" controls. Contrary results were reported by Ho *et al.*,<sup>7</sup> who described longer healing times in "closed" patients (6.9 weeks) compared with "open" procedures (4.9 weeks). Postoperative complications were similar in each group, but minor problems (*e.g.*, pruritus) tended to be more frequent in the "open" procedures.

Time off of work is a very imprecise measure of evaluating posthemorrhoidectomy recovery. Approximately half of the patients in either group worked full-time or part-time. There was great variability in time off work in each group, ranging from one day to three months. This probably reflects the social and employment circumstances of the individuals, rather than a measure of postoperative recovery. However, 55 percent of Harmonic Scalpel® patients returned to work within one week, compared with only 23 percent in the electrocautery group. Three patients in each group (17 percent of the Harmonic Scalpel®

group and 23 percent of the electrocautery group) reported taking in excess of three weeks off work. Although it is inappropriate to extrapolate this finding, this may reflect an easier postoperative recovery for the Harmonic Scalpel® patients, enabling an earlier return to work when the social and employment circumstances permit.

During the course of the evaluation, several distinct advantages and disadvantages of the Harmonic Scalpel® became evident. One of the main advantages, as illustrated during the current study, was less postoperative pain after Harmonic Scalpel® hemorrhoidectomy and the need for fewer postoperative narcotic analgesics. The second attractive feature of the Harmonic Scalpel® hemorrhoidectomy is the excellent hemostasis during the procedure. Hemostasis is accomplished by coaptation of the vessels, which are sealed by denatured proteins. During hemorrhoidectomy, hemostasis was most readily established using the blunt edge of the blade and using the "variable" power mode. This combination was generally used for the internal hemorrhoidal component, this being the most vascular portion of the dissection. The sharp edge of the blade and "full" power mode were generally used for the external components to afford optimum cutting ability through the thicker perianal skin. Because of the less vascular nature of the tissue, the coagulation mode was generally not necessary during the dissection of the external hemorrhoid.

In contrast with electrocautery hemorrhoidectomy, very little smoke is generated by the Harmonic Scalpel®. A local water vapor is generated, which is easily removed in adjacent suction and does not permeate as far as electrocautery smoke. This is a plus for the entire operating room staff. Having mastered the characteristics of the Harmonic Scalpel®, surgical hemorrhoidectomy by an experienced surgeon becomes a much easier and more expeditious procedure. The excellent hemostasis offered by the Harmonic Scalpel® permits an efficient excision of the hemorrhoidal tissue without the need to establish hemostasis from multiple bleeding sites.

One of the early drawbacks of Harmonic Scalpel® hemorrhoidectomy was the presence of a definite learning curve for the procedure. The Harmonic Scalpel® takes slightly longer than electrocautery to divide the hemorrhoidal tissue. This calls for patience and the avoidance of undue traction on the surgical specimen, which is an almost instinctive reaction to the slower rate of cutting. Undue traction on the surgical end of the specimen inevitably results in bleeding

from the lead point of the dissection. The design of the earlier models of handsets for the Harmonic Scalpel® proved clumsy and unwieldy during surgical hemorrhoidectomy with the patient in the prone jack-knife position. The blades in these models were relatively thick and straight, obscuring the line of vision, especially during dissection of the internal hemorrhoid from the internal sphincter. Later designs of the Harmonic Scalpel® with thinner and curved blades have eliminated this problem and provide better visualization of the surgical anatomy.

The significant disadvantage with the Harmonic Scalpel®, as has been noted with all new technologies, is the extra expense incurred. The list price of the disposable hand piece of the Coagulating Shears® model is approximately \$350 and represents a direct addition to the cost of the procedure. The generators cost approximately \$15,000 each, and, because each scalpel requires its own generator, only one Harmonic Scalpel® procedure can be performed at any given time, unless multiple generators are purchased. The remainder of the instrument is sterilized by autoclave. Similar cost concerns were raised by Senagore *et al.*<sup>19</sup> during the evaluation of Nd:YAG laser hemorrhoidectomy. In Senagore *et al.*'s 1993 study,<sup>19</sup> use of the Nd:YAG laser added an additional \$480 per case. Significantly, the same study found no decrease in posthemorrhoidectomy pain in the laser group but, ironically, noted longer healing times. In contrast, the current study demonstrates improved outcomes after surgery and suggests less time lost from work, thus providing significant financial benefits to justify the additional expense.

The current study demonstrates a significant decrease in postoperative pain after Harmonic Scalpel® hemorrhoidectomy and provides a promising avenue for future research. These results must, however, be reproduced by other investigators before a definitive role for the Harmonic Scalpel® can be established.

## ACKNOWLEDGMENTS

The authors thank Kelly Cyrus and Marie Kieffer for ensuring completeness of the patient data forms.

## REFERENCES

1. Goldstein ET, Williamson PR, Larach SW. Subcutaneous morphine pump for postoperative hemorrhoidectomy pain management. *Dis Colon Rectum* 1993;36:439-46.
2. Kilbride M, Morse M, Senagore A. Transdermal fentanyl

- improves management of postoperative hemorrhoidectomy pain. *Dis Colon Rectum* 1994;37:1070-2.
3. O'Donovan S, Ferrara A, Larach S, Williamson P. Intraoperative use of Toradol® facilitates outpatient hemorrhoidectomy. *Dis Colon Rectum* 1994;37:793-9.
  4. Chester JF, Stanford BJ, Gazet J-C. Analgesic benefit of locally injected bupivacaine after hemorrhoidectomy. *Dis Colon Rectum* 1990;33:487-9.
  5. Lacerda-Filho A, Cunha-Melo JR. Outpatient haemorrhoidectomy under local anaesthesia. *Eur J Surg* 1997; 163:935-40.
  6. Neto JA, Quilici FA, Cordeiro F, Reis JA. Open versus semi-open hemorrhoidectomy: a random trial. *Int Surg* 1992;77:84-90.
  7. Ho YH, Seow-Choen F, Tan M, Leong AF. Randomized controlled trial of open and closed haemorrhoidectomy. *Br J Surg* 1997;84:1729-30.
  8. Mathai V, Ong BC, Ho YH. Randomized controlled trial of lateral internal sphincterotomy with haemorrhoidectomy. *Br J Surg* 1996;83:380-2.
  9. O'Bichere A, Laniado M, Sellu D. Stapled haemorrhoidectomy: a feasible day-case procedure. *Br J Surg* 1998; 85:377-8.
  10. Hosch SB, Knoefel WT, Pichlmeier U, *et al.* Surgical treatment of piles: prospective, randomized study of Parks *vs.* Milligan-Morgan hemorrhoidectomy. *Dis Colon Rectum* 1998;41:159-64.
  11. Patel N, O'Connor T. Suture haemorrhoidectomy: a day-only alternative. *Aust N Z J Surg* 1996;66:830-1.
  12. Seow-Choen F, Low HC. Prospective randomized study of radical versus four piles haemorrhoidectomy for symptomatic large circumferential prolapsed piles. *Br J Surg* 1995;82:188-9.
  13. Ui Y. Anoderm-preserving, completely closed hemorrhoidectomy with no mucosal incision. *Dis Colon Rectum* 1997;40(Suppl):S99-S101.
  14. Leff EI. Hemorrhoidectomy-laser *vs.* nonlaser: outpatient surgical experience. *Dis Colon Rectum* 1992;35: 743-6.
  15. Smith LE. Hemorrhoidectomy with lasers and other contemporary modalities. *Surg Clin North Am* 1992;72: 665-79.
  16. Hodgson WJ, Morgan J. Ambulatory hemorrhoidectomy with CO<sub>2</sub> laser. *Dis Colon Rectum* 1995;38:1265-9.
  17. Chia YW, Darzl A, Speakman CT, Hill AD, Jameson JS, Henry MM. CO<sub>2</sub> laser haemorrhoidectomy—does it alter anorectal function or decrease pain compared to conventional haemorrhoidectomy? *Int J Colorectal Dis* 1995;10:22-4.
  18. Wang JY, Chang-Chien CR, Chen J-S, Lai C-R, Tang RP. The role of lasers in hemorrhoidectomy. *Dis Colon Rectum* 1991;34:78-82.
  19. Senagore A, Mazier WP, Luchtefeld MA, MacKeigan JM, Wengert T. Treatment of advanced hemorrhoidal disease: a prospective, randomized comparison of cold scalpel *vs.* contact Nd:YAG laser. *Dis Colon Rectum* 1993;36:1042-9.
  20. McCarus SD. Physiologic mechanism of the ultrasonically activated scalpel. *J Am Assoc Gynecol Laparosc* 1996;3:601-8.
  21. Amaral JF. Laparoscopic cholecystectomy in 200 consecutive patients using an ultrasonically activated scalpel. *Surg Laparosc Endosc* 1995;5:255-62.
  22. Bayer I, Mysolovaty B, Picovsky BM. Rubber band ligation of hemorrhoids. *J Clin Gastroenterol* 1996;23:50-2.
  23. MacRae HM, McLeod RS. Comparison of hemorrhoidal treatment modalities: a meta-analysis. *Dis Colon Rectum* 1995;38:687-94.