

Efficacy of Topical Metronidazole (10 Percent) in the Treatment of Anorectal Crohn's Disease

Edward E. Stringer, M.D., Thomas J. Nicholson, M.D.,
David Armstrong, M.D., F.R.C.S.

Georgia Colon and Rectal Surgical Clinic, Atlanta, Georgia

PURPOSE: The aim of this study was to investigate the efficacy of 10 percent topical metronidazole in the treatment of symptomatic anorectal Crohn's disease. **METHODS:** Patients with symptomatic anorectal Crohn's disease were studied in a prospective, nonblinded, nonrandomized study to evaluate the efficacy of topical 10 percent metronidazole. Perianal Crohn's Disease Activity Index and each component (pain, discharge, induration, sexual dysfunction, and type of pathology) were recorded before treatment and at four weeks. Visual analog pain score (0-10) was recorded before treatment and at weekly intervals for up to four weeks. **RESULTS:** Fourteen patients were studied prospectively for four weeks. Mean Perianal Crohn's Disease Activity Index decreased from 8.8 ± 0.9 before treatment to 4.1 ± 0.7 after four weeks' treatment ($P < 0.0001$). Visual analog pain scores decreased from 5.4 ± 0.7 before treatment to 2.4 ± 0.5 at one week ($P < 0.001$) and to 1.0 ± 0.4 after four weeks' treatment ($P < 0.0001$). Of the Perianal Crohn's Disease Activity Index components, significant decreases were noted in pain and discharge ($P < 0.0001$) and induration ($P < 0.001$). **CONCLUSION:** For patients with perianal Crohn's disease, topical 10 percent metronidazole decreases the Perianal Crohn's Disease Activity Index and anorectal pain. [Key words: Crohn's disease; Metronidazole; Inflammatory bowel disease]

Anorectal Crohn's disease is one of the most problematic and debilitating conditions encountered in colorectal practice. The condition is usually chronic, debilitating, and frequently refractory to current medications. Failure to respond to medical

therapy may ultimately result in proctocolectomy and ileostomy.¹⁻³ Isolated anorectal disease is reported in 3 to 5 percent of Crohn's patients and is found in conjunction with colorectal or enteric disease in one-third to one-half of Crohn's patients.⁴⁻⁷ In spite of previous reports of the painless nature of anorectal Crohn's disease, our experience is that the condition can be inordinately painful because of deeply eroding fissures, edematous skin tags, and painful induration of the perianal region. Diagnosis of Crohn's disease after anorectal surgery is particularly problematic because of protracted postoperative pain, induration, and discharge. The perineum heals very slowly, if at all, and persistent symptoms often lead to early proctocolectomy. If anorectal Crohn's disease is suspected preoperatively, surgery is usually limited to drainage of undrained sepsis and biopsy of suspicious areas, in an attempt to establish the diagnosis.⁸ Additional procedures such as hemorrhoidectomy, fissurectomy, or fistulotomy are avoided if at all possible to avert likely postoperative complications and nonhealing incisions.⁹

First-line medical treatment for anorectal Crohn's disease generally consists of oral metronidazole, which produces symptomatic relief in up to 80 percent of cases. However, improvement is often slow and treatment is usually required on a long-term basis.¹⁰ Side effects from metronidazole (parasthesia, nausea, or gastrointestinal upset) often lead to discontinuation of the medication, with subsequent flare-up of symptoms in approximately 70 percent of pa-

Correspondence to: David Armstrong, M.D., F.R.C.S., Georgia Colon and Rectal Surgical Clinic, 5555 Peachtree Dunwoody Road, Atlanta, Georgia 30342, e-mail: GACRS@aol.com

Dis Colon Rectum 2005; 48: 970-974

DOI: 10.1007/s10350-004-0873-8

© The American Society of Colon and Rectal Surgeons

Published online: 21 March 2005

tients.¹¹ The current study investigates the potential role of topical metronidazole in symptomatic anorectal Crohn's disease.

METHODS

The role of topical 10 percent metronidazole in anorectal Crohn's disease was studied. The diagnosis of Crohn's disease was based on radiologic, endoscopic, and biopsy information. Patients were enrolled over a 12-month period. Informed consent was obtained from all patients. The following variables were recorded for each patient: age, gender, distribution of Crohn's disease (associated enteric or colonic disease), type of disease (fissure, fistula, skin tag, etc.), and previous surgery for Crohn's disease (small-bowel resection, large-bowel resection, anorectal surgery). Current Crohn's-related medications (5-ASA products, prednisone, 6-mercaptopurine (6-MP), and Infliximab) were recorded at enrollment. Patients were instructed to continue their current medical regimen at the same dosage throughout the study period. Patients taking high-dose oral steroids (>40 mg prednisone/day) and patients starting a new immunosuppressant within 90 days before enrollment were excluded. Any necessary change in drug regimen during the four-week study period was noted. Patients undergoing anorectal surgery within four weeks before enrollment and patients requiring anorectal surgery in the near future were excluded. Patients with surgical diversion of the perianal region (colostomy or ileostomy) were also excluded. Patients requiring surgery during the study period were recorded.

Perianal Crohn's Disease Activity Index¹² (PCDAI) and each component (pain, discharge, induration, sexual dysfunction, and type of disease) were recorded at enrollment for each patient. In addition, visual analog pain scores (VAS 0–10) were recorded at enrollment and at one, two, and four weeks by the patient. Patients were followed up at four weeks after treatment and PCDAI indices were again evaluated.

Dosage and Administration

Metronidazole was compounded as a 10 percent concentration in petrolatum cream (SLA Pharma (UK) Limited, Watford, UK). Dosage of topical metronidazole was designed to approach the standard oral dosage (250 mg, *t.i.d.*) as a topical application. A 2.5-ml application of 10 percent topical metronidazole contains 250 mg of metronidazole, whereas a more typi-

cal one-inch application (700 mg) contains 70 mg of metronidazole. The quantity of medication applied varied with the type of disease and its distribution. Patients were instructed to apply the medication three times a day, preferably after a soak or Sitz bath.

Statistics

Changes in PCDAI at enrollment and four weeks, and changes in VAS score at enrollment, one, two, and four weeks were compared by use of Wilcoxon's signed-rank test.

RESULTS

Fourteen patients were prospectively enrolled in a 12-month study. There were seven males and seven females, with ages from 22 to 77 years (mean \pm standard error of the mean (SEM), 43 ± 5 years). Ten patients had been previously diagnosed with Crohn's disease between 18 months and 20 years before enrollment. Four patients were newly diagnosed at enrollment. Five patients (35 percent) had isolated anorectal Crohn's disease, eight patients (57 percent) had associated colitis, and one patient (8 percent) had ileocolic Crohn's disease. Anorectal disease consisted of seven patients (50 percent) with one or more fistula-in-ano, five (35 percent) with fissure-in-ano, one patient (7 percent) had both fistula and fissure, and one (7 percent) had a fissure and anal stenosis. Thirteen of the fourteen patients (93 percent) had undergone at least one previous anorectal procedure, usually incision and drainage of an abscess. One patient had undergone a previous ileocolic resection and one patient had undergone two previous segmental colon resections.

At enrollment, six patients were receiving no specific Crohn's-related medication. Three patients (43 percent) were receiving an Infliximab-based combination of medications, three (43 percent) were receiving a prednisone-based or 6-MP-based combination, and two (14 percent) were taking a 5-ASA-based regimen. In addition to these regimens, four patients (28 percent) were receiving metronidazole orally, up to a maximum of 1 g daily.

During the four-week period of topical 10 percent metronidazole treatment, mean PCDAI (\pm SEM) decreased from 8.8 ± 0.9 at enrollment to 4.1 ± 0.7 at four weeks ($P < 0.0001$). Each individual component of PCDAI was analyzed individually (Table 1). Significant decreases were noted in the pain ($P < 0.0001$),

Table 1.
Perianal Crohn's Disease Activity Index (PCDAI) and Its Components at Enrollment and After 4 Weeks' Treatment with Topical Metronidazole

	Pain	Induration	Discharge	Sexual Dysfunction	Type of Disease	PCDAI Total
Enrollment	2.4 ± 0.3	1.7 ± 0.3	2.1 ± 0.3	0.7 ± 0.3	1.8 ± 0.2	8.8 ± 0.9
4 weeks	0.5 ± 0.1 ^a	0.4 ± 0.1 ^b	1.0 ± 0.2 ^a	0.3 ± 0.2	1.7 ± 0.2	4.1 ± 0.7 ^a

^a $P < 0.0001$, Wilcoxon's rank-sign test.

^b $P < 0.001$, Wilcoxon's rank-sign test.

discharge ($P < 0.0001$), and induration ($P < 0.001$) components during the four-week study period. Mean VAS scores (\pm SEM) decreased from 5.4 ± 0.7 at enrollment to 2.4 ± 0.5 at one week ($P < 0.001$) and 1.0 ± 0.4 at four weeks ($P < 0.0001$) (Fig. 1). Thirteen of the 14 patients reported a decrease in VAS within one week and a decrease in PCDAI at four weeks. One patient reported no change in either VAS or PCDAI and experienced persistent coccygeal pain and point tenderness throughout the study.

During the four-week study period, no patient required interval surgery for anorectal Crohn's disease, and no patient required additional immunosuppressant or antibiotic regimens. Infliximab infusions had been recommended in two patients before enrollment in the study to control severe postoperative anorectal pain. Both patients responded rapidly to treatment with topical 10 percent metronidazole and the planned Infliximab infusions were cancelled. One patient had been receiving Infliximab infusions on a monthly basis before enrollment in the study and this was decreased to every two months as a result of clinical response to topical metronidazole. Two additional patients were receiving Infliximab at enrollment required continued infusions at the same dose and frequency during and after the study to control colonic symptoms (abdominal pain and diarrhea).

DISCUSSION

Metronidazole is a synthetic imidazole antibiotic that was first developed in the 1950s. The antibiotic is effective against anaerobic bacteria and protozoa but also has a separate and less well defined anti-inflammatory action. The latter property has been successfully used in topical treatment of skin diseases such as rosacea.¹³⁻¹⁵ Metronidazole is the first-line treatment for suppurative anorectal Crohn's disease; however, symptomatic response is usually slow (approximately 8 weeks) and chronic therapy is usually required to maintain remission.¹⁰

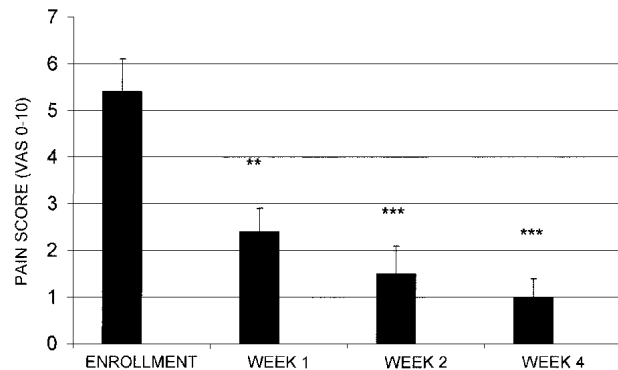


Figure 1. Anorectal pain, measured by visual analog pain scores (VAS), at enrollment and after 4 weeks' treatment with topical 10 percent metronidazole (** $P < 0.001$; *** $P < 0.0001$, Wilcoxon's signed-rank test).

A number of potentially serious side effects can be associated with the use of oral metronidazole. These include neurologic side effects such as paresthesia, which may be permanent and debilitating. Gastrointestinal side effects are common, including nausea, anorexia, and a characteristic metallic taste in the mouth. Rare but potentially fatal hematological side effects have been reported.¹⁶ The onset of side effects usually leads to the medication being discontinued, which in turn frequently leads to recurrent symptoms.

Second-line treatment usually consists of 6-MP, but any benefit from this medication in anorectal Crohn's disease is disputed. In 1980 Present *et al.*¹⁷ reported the results of a two-year prospective, double-blind, crossover study, in which improvement occurred in 67 percent of Crohn's patients after 6-MP infusion, compared with 8 percent of placebo controls. By contrast, Makowiec and colleagues¹⁸ failed to demonstrate any clear-cut benefit from immunosuppressive therapy in perianal Crohn's disease. Side effects from 6-MP are reported in 10 percent of patients, including leucopenia, bone marrow suppression, nausea, and pancreatitis.

Infliximab, has a promising but evolving role in treating anorectal disease.^{19,20} Present *et al.*²⁰ reported closure of Crohn's fistula (90 percent of whom

were “perianal”) in 46 percent of patients treated with Infliximab, compared with 13 percent closure in placebo controls. In spite of a useful role for Infliximab in treatment of anorectal Crohn’s disease, significant drawbacks do exist. The medication is expensive, repeat infusions are required on an indefinite basis, and potentially life-threatening complications have been reported.

The current study demonstrates a potential therapeutic role for 10 percent topical metronidazole in treating anorectal Crohn’s disease. The rationale for using topical 10 percent metronidazole lay in avoiding potential side effects from the drug when taken orally. Initial trials of 1% metronidazole proved sub-optimal. A 10 percent metronidazole formulation was used in an attempt to deliver an effective dose of medication locally to the area of disease. A one-inch application of 10 percent metronidazole ointment contains approximately 70 mg of active drug. Absorption studies (using aqueous metronidazole preparations) suggest that following a single application of 10 percent metronidazole, serum concentrations would be less than 5 percent of those seen following a single 500-mg oral dose.²¹ No local or systemic side effects were noted from the topical preparation during the present study.

When each component of the PCDAI (pain, discharge, induration, sexual dysfunction, and type of disease) was analyzed individually, significant decreases were noted only in the categories of pain, discharge, and induration. A significant decrease in anorectal pain is corroborated by a decrease in VAS results recorded throughout the study period. A representative response is illustrated in Figure 2, which shows an anterior fissure-in-ano in a middle-aged male before treatment (Fig. 2A) and after 2 weeks’ treatment with topical metronidazole (Fig. 2B). A decrease in overall size of the fissure occurred as well as a decrease in granulation tissue, especially in the perianal region. The patient experienced concomitant decrease in both PCDAI and VAS values. No significant decrease was seen in type of disease (principally the number of secondary fistula openings) or sexual dysfunction components of the PCDAI. Because no decrease in number of fistula opening was identified, the medication does not appear to have an important role in closure of fistula tracts, although discharge from the fistulas was significantly improved. No decrease in the sexual dysfunction component was noted in the current study. In practice, this component relates mostly to female patients with perianal

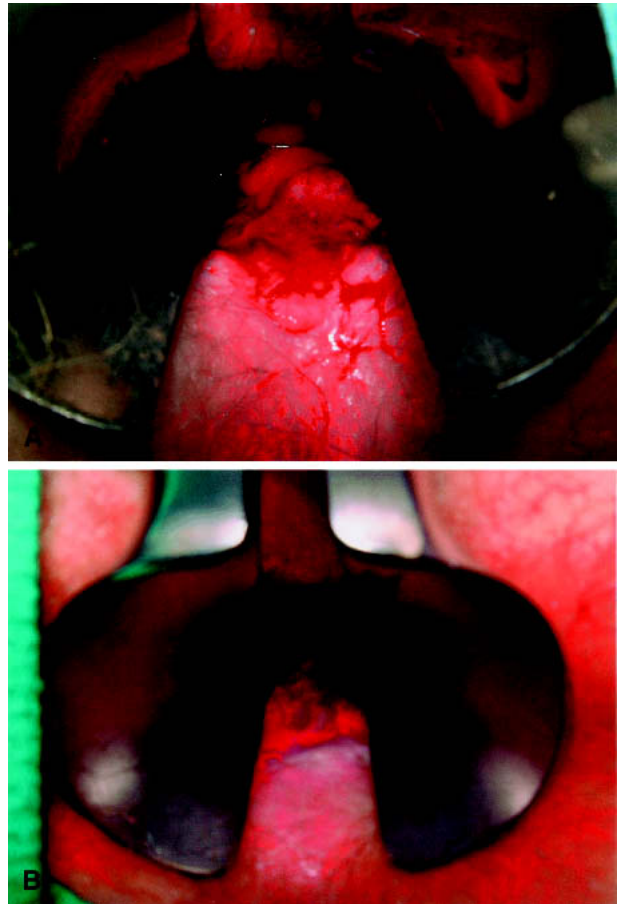


Figure 2. Anorectal Crohn’s disease with anterior fissure-in-ano. A. Initial examination of the patient under anesthesia revealed a florid, granulating fissure-in-ano in the anterior midline. B. After two weeks of topical metronidazole treatment, the patient reported relief of pain and diminished discharge. The fissure has undergone significant shrinkage, leaving only a sclerotic ulcer in the transitional zone.

Crohn’s disease, rather than males. Objective evaluation of sexual dysfunction is difficult to elicit in many cases, because it presupposes that the individual is sexually active, and patients are often reluctant or embarrassed to discuss the issue.

An additional benefit of topical metronidazole noted in the current study was its rapidity of action. Patients reported noticeable symptom relief within two weeks of starting treatment. This contrasts with the prolonged treatment often required with oral metronidazole before response is seen. With 6-MP therapy, noticeable benefits may not be seen until after several weeks. This benefit of topical metronidazole may be a function of increased local tissue concentrations with its direct application to the disease site. The specific mechanism of action of topical

metronidazole in anorectal Crohn's disease may be related to its antibiotic actions, its anti-inflammatory properties, or a combination of both.

Infliximab treatments were either cancelled or decreased in three patients. An additional two patients required continued Infliximab treatment at the same dose and frequency as required previously, to control colonic symptoms. No correlation between magnitude of response and preexisting medications (including oral metronidazole) was identified in the current study. Given the local action of topical metronidazole and the lack of systemic absorption, any therapeutic role will be confined to local control of anorectal symptoms, in conjunction with additional systemic therapies to control more proximal disease. Because anorectal Crohn's symptoms are often the most debilitating and difficult to control, topical metronidazole has an important role in these cases. To further characterize the role 10 percent topical metronidazole in management of anorectal Crohn's disease, both a prospective, randomized, controlled trial and longer-term prospective studies are under way.

REFERENCES

1. Rutgeerts P. Management of perianal Crohn's disease. *Can J Gastroenterol* 2006;14(Suppl C):7C-12C.
2. McClane SJ, Rombeau JL. Anorectal Crohn's disease. *Surg Clin North Am* 2001;81:169-83.
3. Egan LJ, Sandborn WJ. Advances in treatment of Crohn's disease. *Gastroenterology* 2004;126:1574-81.
4. Schwartz DA, Loftus EV Jr, Tremaine WJ, *et al*. The natural history of fistulizing Crohn's disease in Olmsted County, Minnesota. *Gastroenterology* 2002;122:875-80.
5. Platell C, Mackay J, Collopy B, Fink R, Ryan P, Woods R. Anal pathology in patients with Crohn's Disease. *ANZ J Surg* 1996;66:5-9.
6. Solomon MJ. Fistulae and abscesses in symptomatic perianal Crohn's Disease. *Int J Colorectal Dis* 1996;11:222-6.
7. Williamson PR, Hellinger MD, Larach SW, Ferrara A. Twenty-year review of the surgical management of perianal Crohn's Disease. *Dis Colon Rectum* 1995;38:389-92.
8. Makowiec F, Jehle EC, Becker H-D, Starlinger M. Perianal abscess in Crohn's disease. *Dis Colon Rectum* 1997;40:443-50.
9. Pescatori M, Interisano A, Basso L, *et al*. Management of perianal Crohn's disease: results of a multicenter study in Italy. *Dis Colon Rectum* 1995;38:121-4.
10. Jakobovits J, Schuster MM. Metronidazole therapy for Crohn's Disease associated fistulae. *Am J Gastroenterol* 1984;79:533-40.
11. Brandt LJ, Bernstein LH, Baley SJ, *et al*. Metronidazole therapy for perineal Crohn's disease: a follow up study. *Gastroenterology* 1982;83:383-7.
12. Irvine EJ. Usual therapy improves perianal Crohns disease as measured by a new Disease Activity Index. *J Clin Gastroenterol* 1995;70:27-32.
13. Gupta AK, Chaudhry M. Topical metronidazole for rosacea. *Skin Therapy Lett* 2002;7:1-6.
14. Dahl MV, Jarrett M, Kaplan D, Tuley MR, Baker MD. Once-daily topical metronidazole cream formulations in the treatment of the papules and pustules of rosacea. *J Am Acad Dermatol* 2001;45:723-30.
15. Dahl MV, Katz HI, Krueger GG, *et al*. Topical metronidazole maintains remissions of rosacea. *Arch Dermatol* 1998;134:679-83.
16. Metronidazole. American Hospital Formulary Service Drug Information. Bethesda: American Society of Health System Pharmacists, 2002:864-75.
17. Present DH, Korelitz BI, Wisch N, Glass JL, Sachman DB, Pasternack BS. Treatment of Crohn's disease with 6-Mercaptopurine. A long-term, randomized double-blind study. *N Engl J Med* 1980;302:981-7.
18. Makowiec F, Jehle EC, Starlinger M. Perianal abscess in Crohn's disease. *Dis Colon Rectum* 1985;28:709-11.
19. Present DH, Rutgeerts P, Targan S, *et al*. Infliximab for the treatment of fistulae in patient with Crohn's Disease. *N Engl J Med* 1999;340:1398-405.
20. Ricart E, Sandborn WJ. Infliximab for the treatment of fistulas in patients with Crohn's disease. *Gastroenterology* 1997;117:1247-8.
21. Thomson Metrogel: 1867-1869. 58th ed. Montvale, NJ: Thomson PDR, 2004.